

# The Development of Retractable Foreskin in the Child and Adolescent

A publication of Doctors Opposing Circumcision

[www.doctorsopposingcircumcision.org](http://www.doctorsopposingcircumcision.org)

Seattle, Washington

By Morris L. Sorrells, M.D. and G. Hill

**Introduction.** There is much uncertainty among health care workers about when the foreskin of boy should become retractable.<sup>1</sup> This has caused many false diagnoses of phimosis, followed by unnecessary circumcision, when, in fact, the foreskin is developmentally normal.

**History.** A British pediatrician, Douglas Gairdner, provided the first data on development of retractile foreskin was in 1949.<sup>2</sup> His data have been incorporated into many textbooks and still are repeated in the medical literature today. Gairdner said that 80% of boys should have a retractable foreskin by the age of two years, and 90% of boys should have retractable prepuce by the age of three years.

Unfortunately, Gairdner's data are inaccurate,<sup>3,4</sup> so most healthcare providers have been taught inaccurate data. Retractability usually occurs much later than previously believed. This article provides accurate data, derived from newer and better studies, for healthcare providers.

## Current View

Almost all boys are born with the foreskin fused with the underlying glans penis. Most also have narrow foreskin that cannot retract. Nonretractile foreskin is normal at birth and remains common until after late puberty (age 18). Some boys develop retractile foreskin at an early age and about 2 percent of males have nonretractile foreskin throughout life. Nonretractile foreskin is not a disease and does not generally require treatment unless desired by an adult.

There are three possible conditions that cause nonretractile foreskin:

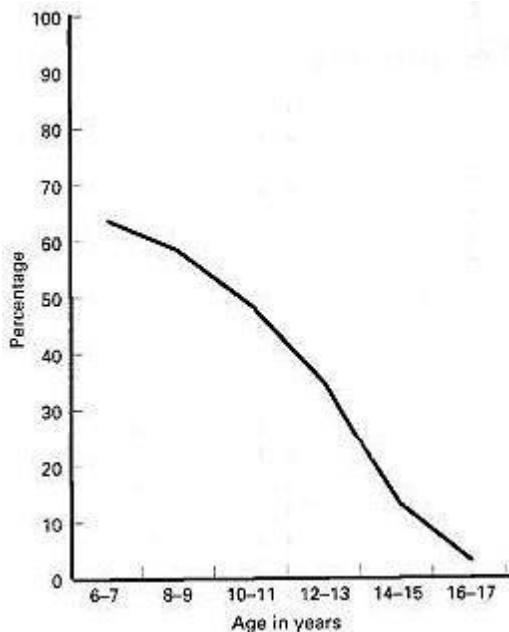
- Fusion of the foreskin with the glans penis
- Tightness of the foreskin orifice
- Frenulum breve (short frenulum) (which is rare and cannot be diagnosed until the previous two reasons have been eliminated)

The first two reasons are normal in childhood and are not pathological in children. The third can be treated conservatively, retaining the foreskin.

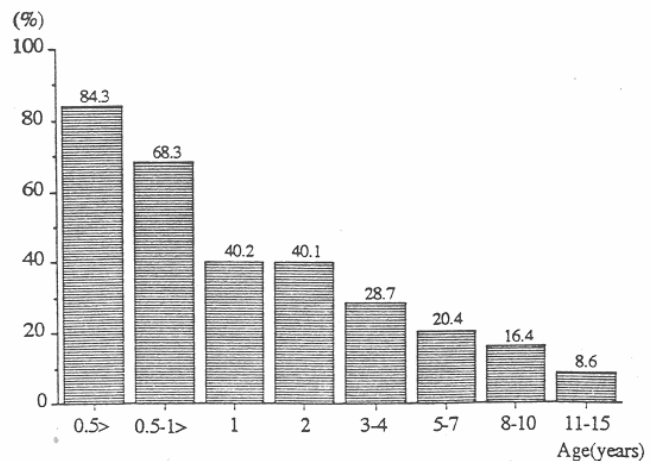
**Infants and preschool.** Kayaba et al. (1996) reported that before six months of age, no boy had a retractable prepuce; 16.5 percent of boys aged 34 had a fully retractable prepuce.<sup>5</sup> Imamura (1997) examined 4521 infants and young boys. He reported that the foreskin is retractile in 3% of infants aged one to three months, 19.9% of those aged ten to twelve months, and 38.4% of three year old boys. Ishikawa and Kawakita (2004) reported no retractability at age one, (but

increasing to 77% at age 11-15).<sup>7</sup> Nonretractile foreskin is the more common condition in this age group. Compare these data with Gairdner's data!

**Schoolage and adolescence.** Jakob Øster, a Danish physician who conducted school examinations, reported his findings on the examination of schoolboys in Denmark, where circumcision is rare.<sup>8</sup> Øster (1968) found that the incidence of fusion of the foreskin with the glans penis steadily declines with increasing age and foreskin retractability increases with age.<sup>8</sup> Kayaba et al (1996) also investigated the development of foreskin retraction in boys from age 0 to age 15.<sup>5</sup> Kayaba et al. also reported increasing retractability with increasing age. They reported that about only 42% of boys aged 8-10 have fully retractile foreskin, but the percentage increases to 62.9% in boys aged 11-15.<sup>5</sup> Imamura (1997) reported that 77% of boys aged 11-15 had retractile foreskin.<sup>6</sup> Thorvaldsen and Meyhoff (2005) conducted a survey of 4000 young men in Denmark.<sup>9</sup> They report that the mean age of first foreskin retraction is 10.4 years in Denmark.<sup>9</sup> Nonretractile foreskin is the more common condition until about 10-11 years of age.



Percentage of boys with fused foreskin by age, according to Øster.



Percentage of boys with tight ring totally nonretractile foreskin according to Kayaba et al.

**Discussion.** Boys usually are born with a nonretractile foreskin. The foreskin gradually becomes retractable over a variable period of time ranging from birth to 18 years or more. There is no “right” age for the foreskin to become retractable. Nonretractile foreskin does not threaten health in childhood and no intervention is necessary. Many boys only develop retractable foreskin after puberty. Education of concerned parents usually is the only action required.<sup>10</sup>

As one pediatric text states, “The prepuce, foreskin, is normally not retractile at birth. At age 6 years, 80% of boys still do not have fully retractile foreskin. By age 17 years, however, 97 to 99% of uncircumcised males have fully retractile foreskin. Natural separation between the glans and the ventral surface of the foreskin occurs with the secretion of skin oils and desquamation of epithelial cells, smegma. .No treatment is required for the lumps or smegma, and in particular,

there is no indication ever for forceful retraction of the foreskin from the glans. Especially in the newborn and infant, this produces small lacerations in addition to severe abrasion of the glans. The result is scarring and resultant secondary phimosis. Thus it is incorrect to teach mothers to retract the foreskin.”<sup>11</sup>

**Avoidance of premature retraction.** Caregivers and healthcare providers must be careful to avoid premature retraction of the foreskin, which is contrary to medical recommendations, painful, traumatic, tears the attachment points (synechiae), may cause infection, is likely to generate medicolegal problems, and may cause paraphimosis, with the tight foreskin acting like a tourniquet. The first person to retract the boy’s foreskin should be the boy himself.<sup>3</sup>

**Catheterization does not require retraction.** It is *not necessary* to forcibly retract child’s foreskin in order to insert a urinary catheter. The foreskin should *never* be torn off the glans penis when inserting a catheter. To insert a catheter in an uncircumcised male, gently retract the foreskin only to visualize the meatus. Full retraction runs the risk of creating paraphimosis. If the foreskin cannot be retracted at all, align the meatus with the opening of the foreskin and gently insert the catheter.<sup>12</sup>

**Making the foreskin retractable.** Occasionally a male reaches adulthood with a nonretractile foreskin. Some men with nonretractile foreskins happily go through life and father children. Other men may want to make their foreskins retractable. The foreskin usually can be made retractable by:

- Manual stretching<sup>13,14</sup>
- Application of topical steroid ointment<sup>15,16</sup>
- A combination of stretching plus topical steroid ointment<sup>17</sup>
- Preputial plasty<sup>18</sup>

Male circumcision is an outmoded treatment for nonretractile foreskin, but it is still recommended by many urologists because of lack of adequate information and understanding of alternative methods of relief. Nevertheless, circumcision should be avoided because of pain, trauma, cost,<sup>18</sup> complications,<sup>19</sup> difficult recovery, permanent injury to the appearance of the penis, loss of pleasurable erogenous sensation,<sup>20,21</sup> and impairment of erectile and ejaculatory functions.<sup>22-24</sup>

## References:

1. Simpson ET, Barraclough P. The management of the paediatric foreskin. *Aust Fam Physician*. 1998;27(5):381-3.
2. Gairdner D. The fate of the foreskin: a study of circumcision. *Br Med J*. 1949;2:1433-7.
3. Wright JE. Further to the "Further Fate of the Foreskin." *Med J Aust*. 1994;160:134-5.
4. Hill G. Circumcision for phimosis and other medical indications in Western Australian boys. *Med J Aust*. 2003;178(11):587.
5. Kayaba H, Tamura H, Kitajima S, et al. Analysis of shape and retractability of the prepuce in 603 Japanese boys. *J Urol*. 1996;156(5):1813-5.
6. Imamura E. Phimosis of infants and young children in Japan. *Acta Paediatr Jpn*. 1997;39(4):403-5.
7. Ishikawa E, Kawakita M. [Preputial development in Japanese boys.] *Hinyokika Kiyo*. 2004;50(5):305-8. Japanese.
8. Øster J. Further fate of the foreskin: incidence of preputial adhesions, phimosis, and smegma among Danish schoolboys. *Arch Dis Child*. 1968;43:200-3.
9. Thorvaldsen MA, Meyhoff H. Patologisk eller fysiologisk fimose? *Ugeskr Læger*. 2005;167(17):1858-62. Norwegian.
10. Spilsbury K, Semmens JB, Wisniewski ZS, et al. Circumcision for phimosis and other medical indications in Western Australian boys. *Med J Aust*. 2003 178 (4):155-8.
11. Rudolph, AM, Hoffman, MD, Pediatrics, Appleton and Lange, Norwalk, CT & Los Altos, CA, 1987, 18<sup>th</sup> Ed., Ch. 23.13.1 "Penis" at p.1205.
12. Robson WLM, Leung AKC, Thomason MA. Catheterization of the bladder in infants and children. *Clin Pediatr*. 2006;45(9):795-800.
13. Dunn HP. Nonsurgical management of phimosis. *Aust N Z J Surg*. 1989;59(12):963.
14. Beaugé M. The causes of adolescent phimosis. *Br J Sex Med*. 1997;Sept/Oct:26.
15. Orsola A, Caffaratti J, Garat JM. Conservative treatment of phimosis in children using a topical steroid. *Urology*. 2000;56(2):307-10.
16. Ashfield JE, Nickel KR, Siemens DR, et al. Treatment of phimosis with topical steroids in 194 children. *J Urol*. 2003;169(3):1106-8.
17. Zampieri N, Corroppo M, Giacomello L, et al. Phimosis: Stretching methods with or without application of topical steroids? *J Pediatr*. 2005;147(5):705-6.
18. Van Howe RS. Costeffective treatment of phimosis. *Pediatrics*. 1998;102(4)/e43.
19. Williams N, Kapila L. Complications of circumcision. *Brit J Surg*. 1993;80:1231-6.
20. Denniston GC, Hill G. Circumcision in adults: effect on sexual function. *Urology*. 2004;64(6):1267.
21. Sorrells, ML, et al. Finetouch pressure thresholds in the adult penis. *BJU Int*. 2007;99:864-9.
22. Shen Z, Chen S, Zhu C, et al. [Erectile function evaluation after adult circumcision.] *Zhonghua Nan Ke Xue*. 2004;10(1):18-9. Chinese.
23. Masood S, Patel HRH, Himpson RC, et al. Penile sensitivity and sexual satisfaction after circumcision: Are we informing men correctly? *Urol Int*. 2005;75(1):62-5.
24. Podnar S. Clinical elicitation of the peniloscavernosus reflex in circumcised men. *BJU Int*. 2011;209:582-5.